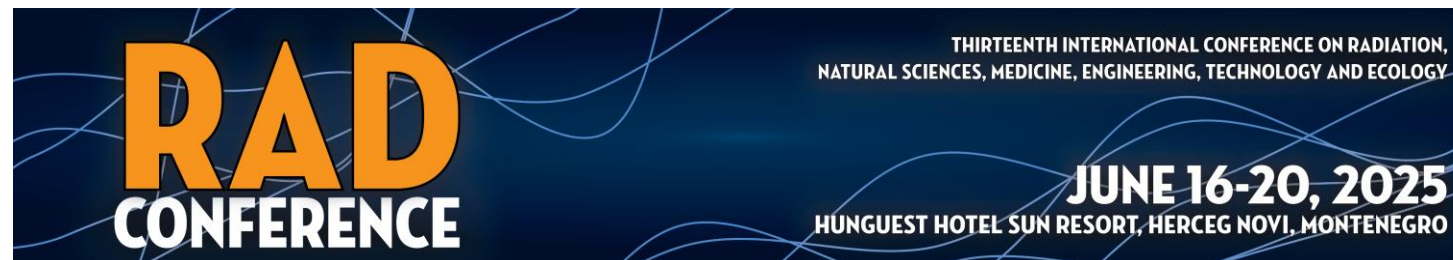


# A Relapse of Multiple Sclerosis Classifiable as an Acute Clinical Event with Stable Magnetic Resonance Imaging (MRI) (ACES)

Author: Sotgiu Anna Maria

Text taken from the thesis of the II Level Master's Degree  
in Psychoneurobiology  
at Sapienza University of Rome  
academic year 2023 2024



# The Multiple Sclerosis (MS)

Multiple Sclerosis is defined as an inflammatory demyelinating disease with autoimmune pathogenesis that mainly affects the axons of the Central Nervous System (di Nuzzo & Gradini, 2017).

In MS, an abnormal activation of T lymphocytes occurs, in particular T helper 1 and T helper 17 that release cytokines and promote inflammation contributing to the destruction of myelin.

The humoral immune system is also involved and a small number of B lymphocytes infiltrate the CNS and specific autoantibodies for myelin have been identified on the myelin sheaths.

# The Relapse of Multiple Sclerosis

An MS 'Relapse' is defined as a monophasic clinical episode with symptoms reported by the patient and objective findings typical of MS, developing acutely or sub acutely, lasting more than 24 hours, and occurring in the absence of fever or infection.

# ACES and RAM (Gavoille et al., 2024)

ACES are clinical events identified as MS relapses with Stable Magnetic Resonance Imaging (MRI). These are not associated with new T2 lesions or gadolinium-enhanced T1 lesions on MRI of the brain and spinal cord (Gavoille et al., 2024).

RAM are events classified as relapses with active MRI in which a new T2 lesion or gadolinium-enhanced T1 lesion appeared on brain or spinal cord MRI.

# The clinical case

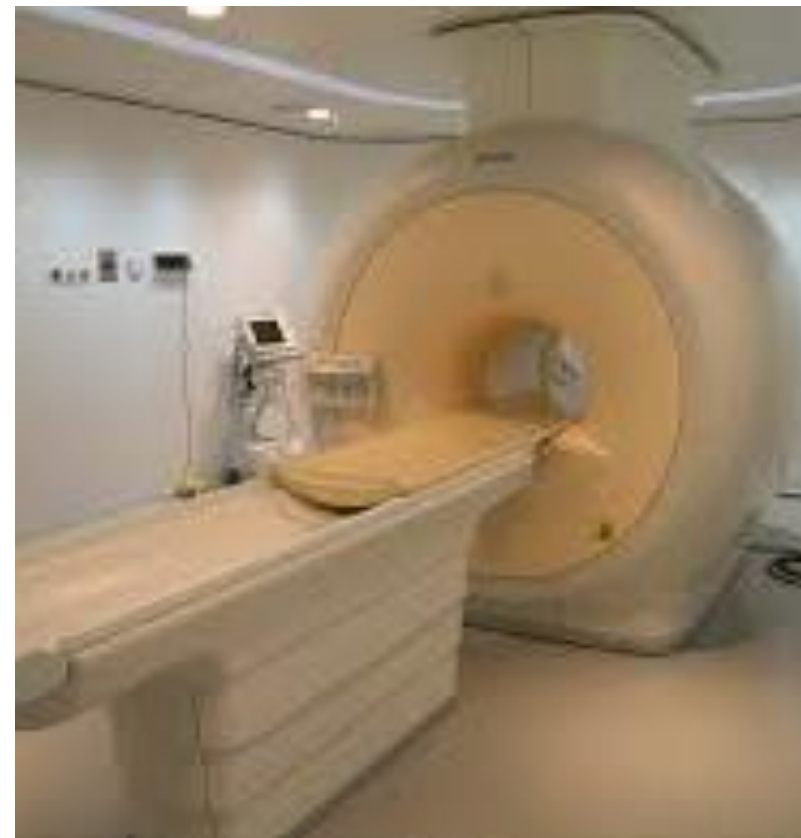The clinical case concerns a person with Multiple Sclerosis (MS) and comorbid osteoporosis who likely experienced an MS relapse classifiable as an ACES. This case aims to provide useful information to clinicians dealing with MS relapses and their onset.

The clinical event concerned a 54-year-old female patient, affected by MS since the age of 29 and with a comorbidity of osteoporosis since the age of 42. For both conditions, the patient had undergone medical therapies and periodic clinical check-ups over the years.

# Patient control Magnetic Resonance Images

Regarding MS, control MRIs (brain, cervical, and dorsal, with contrast medium) have been performed over the years at an annual frequency, and those conducted in the last six years before the described event, have shown findings indicative of neuroradiological disease stability.

Even the most recent of these control MRIs, performed 16 days before the acute clinical event in question, showed unchanged MRI findings compared to the past.



# The symptoms of Relapse

The relapse began suddenly, and the main symptoms, reported by the patient, lasted more than 24 hours and were described as leg cramps while lying down, a sensation of numbness in the right foot and leg and altered sensitivity in the sole of the right foot.

# Medical prescriptions

Following the onset of symptoms, the general practitioner conducted laboratory tests involving hematology, clinical chemistry, and virology, with the most significant results reported later in the text.

Additionally, a specialist neurologist, following a medical examination, diagnosed a suspected clinical relapse of MS and prescribed an MRI (brain, cervical, and dorsal, with contrast medium), which was performed 27 days after the onset of symptoms.

# Laboratory test results

Laboratory test results indicated an increase in relative and absolute eosinophil levels (9.90%; #0.81 x 10<sup>3</sup>/uL) and a decrease in hemoglobin (11.2 g/dL), variations already known in the patient, as well as a decrease in relative neutrophil levels (35.5%).

Varicella IgG antibodies were present with a chemiluminescence value of 4.60, and Varicella IgM antibodies were absent.

# The results of the MRI conducted after the patient's Relapse

The brain, cervical, and dorsal spine MRI with contrast medium showed no new lesions or pathological enhancements in the brain and spinal cord compared to the aforementioned last control MRI, performed 45 days earlier.

# Patient's therapy

The therapies taken by the patient before the onset of symptoms included:

folina (5 mg),

Tardyfer (80 mg),

Prolia (Denosumab),

and

Tyruko (Natalizumab-sztn).

These medications were taken respectively 40, 10, and 2 days before the onset of the relapse, which occurred abruptly during nighttime hours.

# Some other information on Patient's therapy

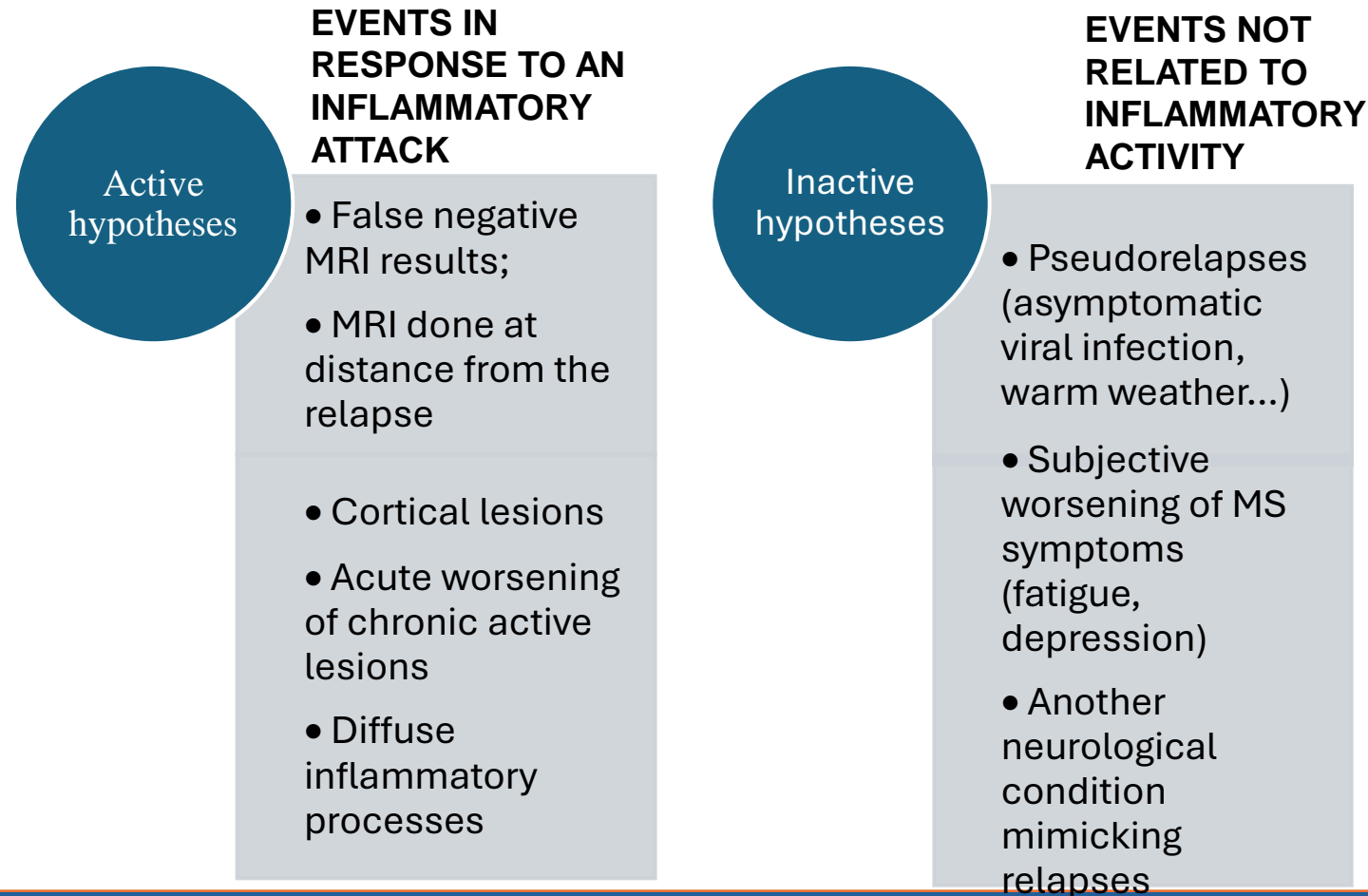
The patient, who had been on Tysabri (Natalizumab) therapy for 14 years, had been switched from the original drug to the biosimilar Tyruko (Natalizumab-sztn) two days before the onset of symptoms.

The patient, affected by osteoporosis and treated with Prolia (Denosumab), had received a subcutaneous injection of the drug 10 days before the onset of the symptoms, while therapy with folina and tardyfer had started 50 days prior.

# Treatment of Relapse

Ninety days after the onset of symptoms, the patient was treated with 3 g/IV of methylprednisolone and underwent a change in immunomodulatory therapy for MS, which consisted of transitioning from Natalizumab-sztn to Mavenclad (Cladribine) tablets, in accordance with the guidelines of a paper prescription form for DMT drugs published in the Official Gazette of the Italian Republic.

# The proposed pathogenetic hypotheses (Gavoille et al. 2024)



# A personal hypothesis

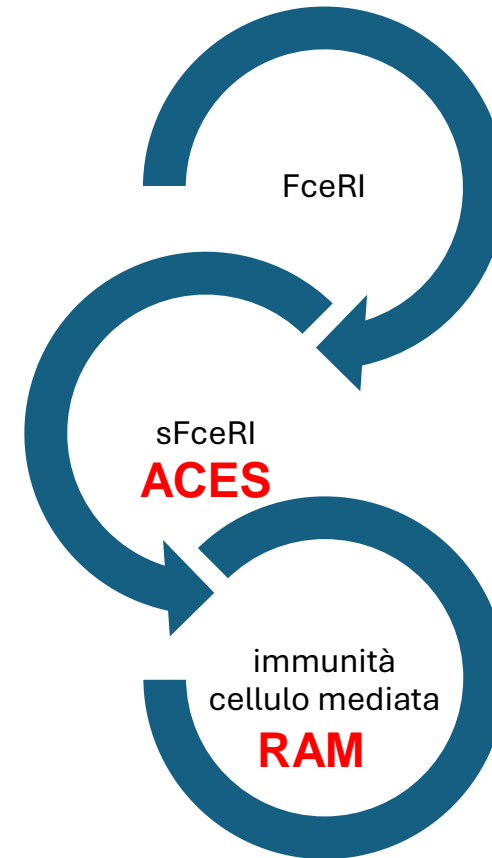
It is hypothesized that the presence of ‘allergenic determinants’ in the myelin (Mikol et al., 2006) of the CNS, in the presence of environmental adjuvants of IgE response, leads to the activation of the immune response in MS, in genetically predisposed subjects, with consequent activation of the IgE/FceRI receptor complex.

The release of the soluble fraction of the receptor (sFceRI alpha) would induce a conformational change of the FceRI complex and the blocking of the IgE response which, if complete, would completely turn off the response and if incomplete would lead to the activation of the Th1 cell-mediated response.

Implications of the hypothesis: the release of the soluble fraction of the FceRI/IgE complex that blocks the IgE response, would explain the absence of the resonance signal in MS patients in

**ACES**

A Relapse of Multiple Sclerosis Classifiable as an Acute Clinical Event with Stable Magnetic Resonance Imaging (MRI) (ACES)



# Bibliography

- Gavaille, A., Rollet, F., Casey, R., Kerbrat, A., Le Page, E., Bigaut, K., Mathey, G., Michel, L., Ciron, J., Ruet, A., Maillart, E., Labauge, P., Zephir, H., Papeix, C., Defer, G., Lebrun-Frenay, C., Moreau, T., Berger, E., Stankoff, B., Clavelou, P., Thouvenot, E., Heinzlef, O., Pelletier, J., Al-Khedr, A., Casez, O., Bourre, B., Cabre, P., Wahab, A., Magy, L., Camdessanché, J.P., Doghri, I., Moulin, S., Ben-Nasr, H., Labeyrie, C., Hankiewicz, K., Neau, J.P., Pottier, C., Nifle, C., Manchon, E., Lapergue, B., Wiertlewski, S., De Sèze, J., Vukusic, S., Laplaud, D.A.; OFSEP Investigators. Acute Clinical Events Identified as Relapses With Stable Magnetic Resonance Imaging in Multiple Sclerosis. *JAMA Neurol.* 2024 Aug 1;81(8):814-823. doi: 10.1001/jamaneurol.2024.1961. PMID: 38949816; PMCID: PMC11217890.
- Di Nuzzo, L., & Gradini, R. (2017). *Fisiopatologia del Sistema Nervoso Centrale*. Padova: Piccin Nuova Libreria S.p.A.
- Mikol, D.D., Ditlow, C., Usatin, D., Biswas, P., Kalbfleisch, J., Milner, A., Calenoff, E. Serum IgE reactive against small myelin protein-derived peptides is increased in multiple sclerosis patients. *J Neuroimmunol.* 2006 Nov;180(1-2):40-9. doi: 10.1016/j.jneuroim.2006.06.030. Epub 2006 Sep 20. PMID: 16996143.